

High Resistance Index in the Feeding Arteries of Indirect Carotid-cavernous Fistulae: A Diagnostic Pitfall

Wei-Ting Lin, Bo-An Chen

Abstract

Carotid-cavernous fistulae (CCFs) are classified into the direct and indirect types, which can be attributed to trauma, atherosclerosis, hypertension, diabetes mellitus, pregnant or postmenopausal status⁽¹⁾. Cerebral angiography is the gold standard for the diagnosis of CCFs. Doppler ultrasound, which typically reveals increased blood flow velocity and decreased resistance index (RI) in the feeding arteries, can assist in the diagnosis⁽²⁻³⁾. We herein report a case of indirect CCF presenting with high RI in the feeding arteries, which is mainly attributed to the generalized atherosclerotic change, and is regarded as a diagnostic pitfall of the CCFs.

Acta Neurol Taiwan 2019;28:75-77

CASE REPORT

A 74-year-old woman, with history of hypertension, diabetes mellitus, dyslipidemia, and coronary artery disease, complained of insidious onset of binocular double vision accompanied with pulsatile tinnitus, right eye swelling and congestion 9 months prior to admission. There was no history of head injury. Acute onset left hemiparesis and slurred speech developed 1 day prior to admission. During hospitalization, neurological examination revealed right lateral rectus limitation, right ptosis and proptosis, dysarthria, and left hemiparesis. Moreover, bruit was heard over left orbital region. Magnetic resonance imaging of the brain revealed hemorrhage at right frontal lobe, right insula, and right cerebellum. Extracranial carotid doppler ultrasound showed moderate eccentric plaques in bilateral carotid

systems, high resistance flow in left common carotid artery (CCA), and high but asymmetric resistance flow in bilateral external carotid artery (ECA) (Fig. 1A, B).

Diagnostic cerebral angiography revealed indirect carotid-cavernous fistula (CCF) with feeding arteries from the branches of bilateral ECAs and right internal carotid artery (ICA) (Barrow type D) (Fig. 1C). We performed transvenous embolization. One month post embolization, her neurological examination remained only right ptosis. The follow-up carotid doppler ultrasound revealed increasing resistance index (RI) in bilateral CCA (before vs after embolization: RI of right CCA, 0.72 vs. 0.75; RI of left CCA, 0.75 vs. 0.79, respectively), right proximal ICA (before vs. after embolization: RI, 0.71 vs. 0.76, respectively), and right ECA (before vs. after embolization: RI, 0.76 vs. 0.88, respectively) (Fig. 1D), which were compatible with her generalized atherosclerotic change

From the Department of Neurology, Mackay Memorial Hospital, Taipei, Taiwan.

Received October 17, 2019.

Revised & Accepted November 20, 2019.

Correspondence to: Bo-An Chen, Department of Neurology, Taipei City Hospital, Renai Branch, Taipei 10341, Taiwan
E-mail address: B101094130@gmail.com

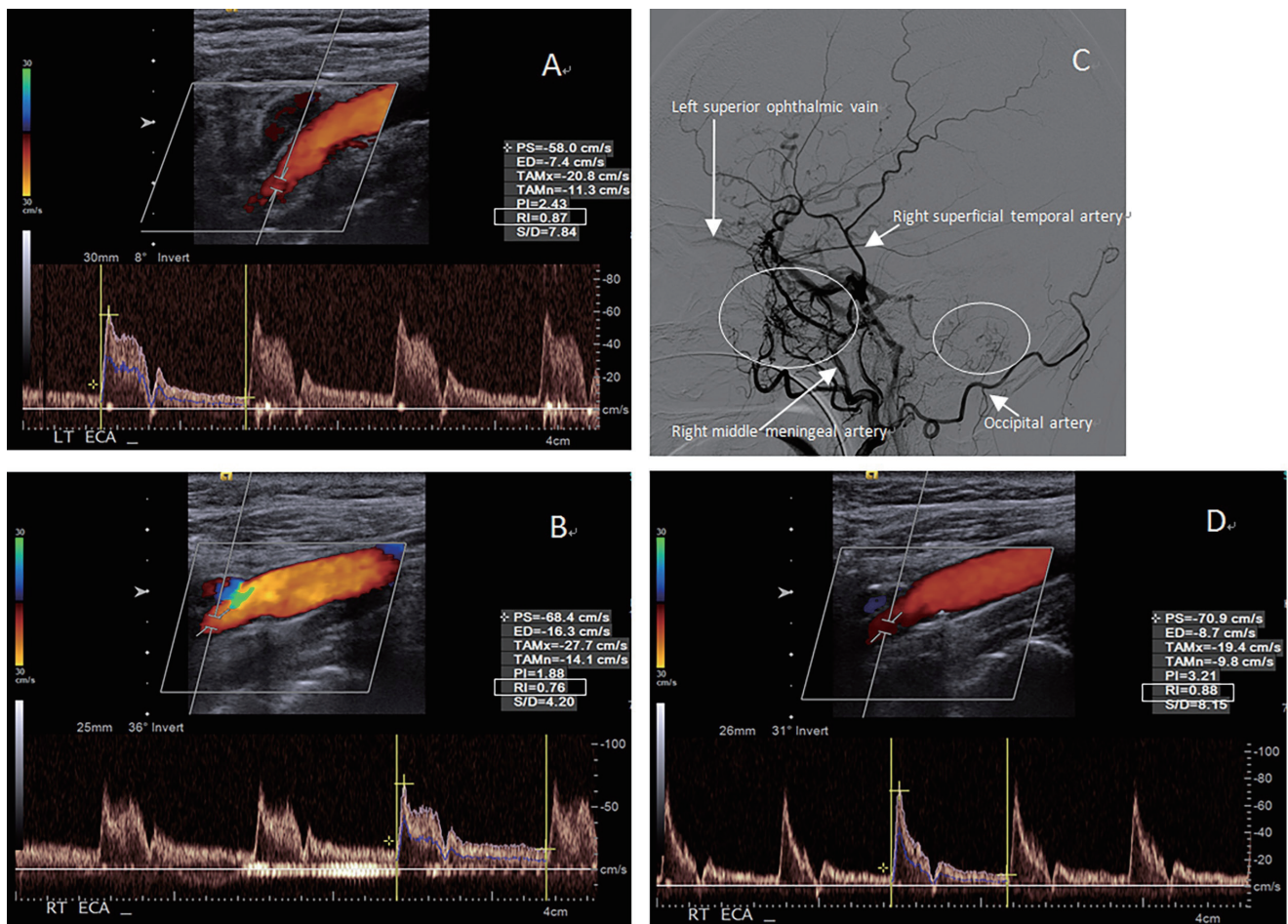


Figure 1: (A,B) Carotid doppler ultrasound revealed high but asymmetric resistance flow in the bilateral ECA (Resistance index [RI] of the right ECA, 0.76; RI of the left ECA 0.87). (C) Diagnostic cerebral angiography demonstrated the main fistulae (the big circle) arising from the right middle meningeal artery, with drainage into the left superior ophthalmic vein, right cerebral vein, and the right cerebellar vein (the small circle); compatible with the obvious alternation resistance flow of the right ECA before and after embolization. (D) RI in the right ECA significantly increased after embolization (before vs. after embolization: RI, 0.76 vs. 0.88).

in bilateral carotid systems detected on carotid doppler ultrasound. Follow-up cerebral angiography after 12 weeks revealed no residual CCF.

DISCUSSION

Type-D CCFs are the most common indirect fistulae, with low-flow dural shunts between the meningeal branches of both the ICA and ECA and the cavernous sinus, and their formation can be attributed to atherosclerosis, hypertension, diabetes mellitus, pregnancy or postmenopausal status⁽¹⁾. Cerebral angiography is

the gold standard for the diagnosis and planning of endovascular interventions for CCFs. Doppler ultrasound, which typically reveals increased blood flow velocity and decreased RI in the feeding arteries, is a good tool for screening and post-interventional follow-up⁽²⁻³⁾. According to previous studies, the decreased RI of ECA [right ECA <0.72; left ECA <0.71] has sensitivity of 74% and a specificity of 89% for the prediction of intracranial dural arteriovenous fistulae⁽⁴⁾. However, the Doppler ultrasound in our patient revealed still high RI in the feeding arteries of bilateral ECA. This atypical finding may be attributed to the patient's generalized atherosclerotic change. Moreover,

the shunting flow of indirect CCFs is usually less than that of the direct type, leading to less alternation in flow volume in the Doppler ultrasound⁽²⁾.

In conclusion, atherosclerosis-related high RI may be a diagnostic pitfall of the CCFs. Diagnostic cerebral angiography should be ultimately performed if patients have clinical presentations that raise concerns regarding CCFs. On the other hand, we suggest that asymmetric resistance flow in the bilateral ECA could be a hint of the existence of CCFs, even if the RIs are bilaterally high. Further studies are needed to confirm our hypothesis.

REFERENCE

1. Korkmazer B, Kocak B, Tureci E, Islak C, Kocer N, Kizilkilic O. Endovascular treatment of carotid cavernous sinus fistula: A systematic review. *World J Radiol.* 2013; 5(4):143-155.
2. Chen YW, Jeng JS, Liu HM, Hwang BS, Lin WH, Yip PK. Carotid and transcranial color-coded duplex sonography in different types of carotid-cavernous fistula. *Stroke.* 2000; 31:701-706.
3. Duan Y, Liu X, Zhou X, Cao T, Ruan L, Zhao Y. Diagnosis and follow-up study of carotid cavernous fistulas with color Doppler ultrasonography. *J Ultrasound Med.* 2005; 24:739-745.
4. Tsai LK, Jeng JS, Wang HJ, Yip PK, Liu HM. Diagnosis of intracranial dural arteriovenous fistulas by carotid duplex sonography. *J Ultrasound Med.* 2004; 23:785-791.