

Spinal Cord Injury—an Unusual Presentation for Advanced Asymptomatic Ankylosing Spondylitis

Khalil Ahmad¹, Sumeera Matee¹, Saeed Bin Ayaz², Hussain Rashid Ihsan²

Abstract-

Purpose: Ankylosing spondylitis affects the axial skeleton over many years, predisposing to osteoporosis and subsequent fractures. However, very rarely, it can be incidentally discovered in spinal cord injury cases.

Case Report: A 44-year-old male veteran who had previously been well and asymptomatic presented with paraparesis secondary to fractured dorsal vertebrae 10 and 11, following fall from a height. He had been referred to our institute for rehabilitation after surgical fixation of his vertebral fractures. X-rays of his spine, done after the injury brought to light the incidental finding of advanced ankylosing spondylitis.

Conclusion: Ankylosing spondylitis can be asymptomatic in a minority of patients, highlighting the importance of keeping a high index of suspicion, especially in patients presenting with vertebral fractures with/without spinal cord injury following relatively minor trauma.

Key Words: asymptomatic ankylosing spondylitis; spinal cord injury; spinal fracture

Acta Neurol Taiwan 2018;25:79-81

INTRODUCTION

Ankylosing spondylitis (AS) is a chronic inflammatory rheumatic disease that predominantly affects the vertebral column and sacroiliac joints. This disease presents with insidious onset low back pain and stiffness that improves with exercise and gets worse in the morning or with inactivity⁽¹⁾. Enthesopathic lesions and peripheral joint involvement occur in 30-50% of all patients⁽¹⁾. Generalized symptoms that may accompany the primary complaints are fatigue, fever and weight loss, which may occur during periods of active disease⁽¹⁾. In a minority of patients, the disease may be silent and is discovered

incidentally⁽²⁾. Presentation with spinal cord injury (SCI) in asymptomatic individuals is a rare occurrence and has never been reported from Pakistan. We present here the case of an individual who presented with SCI secondary to vertebral fracture following trauma and was incidentally found to have AS as the primary predisposing factor.

CASE PRESENTATION

A 44-year-old matriculate veteran had developed weakness in his legs after fall from a height, six feet from ground in April 2014. He was evaluated in the spinal surgery department of a Military Hospital where his

From the ¹Armed Forces Institute of Rehabilitation Medicine (AFIRM), Rawalpindi, Pakistan; ²Combined Military Hospital, Okara Cantonment, Okara, Pakistan.
Received March 19, 2015. Revised June 12, 2015.
Accepted July 20, 2015.

Correspondence to: Saeed Bin Ayaz, Consultant Physiatrist, Combined Military Hospital, Okara Cantonment, Okara, Pakistan.
Email: saeedbinayaz@gmail.com

radiographs revealed fractures of dorsal vertebrae 10 and 11 along with fractures of adjoining ribs. Another finding that was picked up incidentally was the bambooing of the spine and bilateral sacroilitis raising a suspicion of underlying AS (Fig.1). He also had left sided hemo-thorax due to the accompanying rib fractures, which mandated chest intubation. Posterior spinal fixation was done for the fractured vertebrae (Fig.1) and after removal of chest tube and for further stabilization; he was transferred to our institute for comprehensive rehabilitation approximately one month after the injury.

On presenting to us, he was unable to stand but was continent for bowel and bladder and partially independent in self-care activities. He complained of low backache and burning in his legs. He denied any family history of chronic back ache. On examination, his vitals were stable. He had a spasticity of grade-2 according to Modified Ashworth Scale in lower limbs. The power in his upper and lower limbs was 5/5 according to Medical Research Council Scale⁽³⁾ except in iliopsoas, which possessed a power of 4/5. Reflexes were brisk, plantars were upgoing bilaterally and anal tone was intact. The sensations for fine touch and pinprick were normal. He was diagnosed to have SCI at the level of T₁₂ with American Spinal Injury Association Impairment Score (AIS) D⁽⁴⁾. Rest of the examination was unremarkable.

His baseline laboratory investigations and chest x-ray for lung fields were normal. Serum rheumatoid factor and C-reactive protein were negative. The human leucocyte

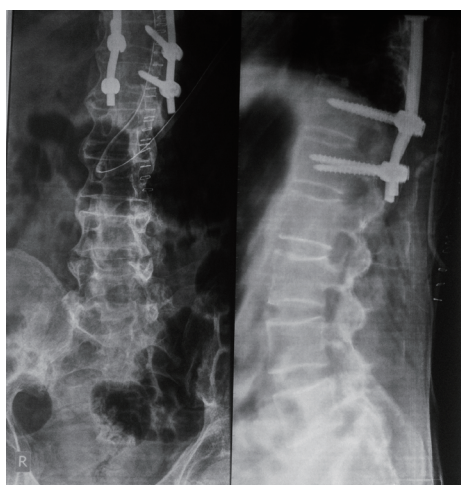


Figure 1. X-ray of the dorsolumbar spine showing bambooing of the spine and posterior spinal fixation for the fractured vertebrae

antigen (HLA)-B₂₇ was positive. His magnetic resonance imaging (MRI) showed a central collapse of DV₁₀ and DV₁₁ and anterior wedging of DV₇ and DV₉ causing an indentation upon the thecal sac and compression on the cord. (Fig. 2) There was a cut-off of the cerebrospinal fluid column at the same level. His serum D-dimers were significantly raised (>800 <1200 ng/ml; normal: <200 ng/ml). Venous Doppler ultrasonography showed partial thrombosis in left popliteal vein with sluggish blood flow.

The patient was started on enoxaparin 30 mg subcutaneously twice daily, pregabalin 50 mg twice daily, acetaminophen 650 mg + orphenadrine 50mg twice daily, omeprazole 20 mg once daily and mecobalamin 500 microgram thrice daily. As soon as his deep venous thrombosis settled and D-dimers returned to normal, electrical muscle stimulation (EMS) to iliopsoas and glutei, range of motion exercises to upper and lower limbs, stretching exercises of iliopsoas, glutei and tibialis anterior, strengthening of quadriceps, ankle dorsiflexors and extensor hallucis longus and gradual physiological standing were commenced. At the completion of his treatment, his pain had reduced to a bearable intensity and he was ambulating without support.

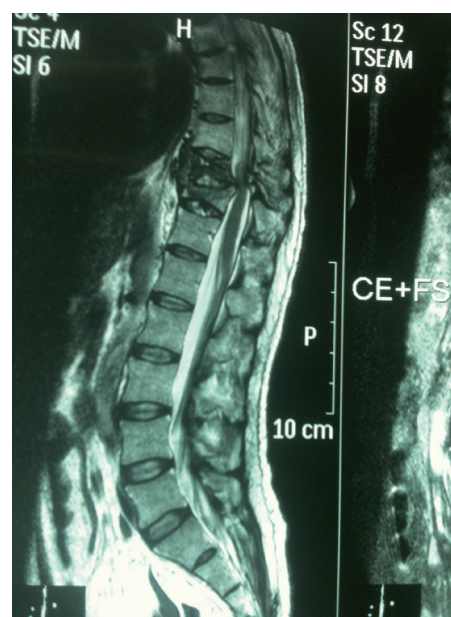


Figure 2. Magnetic resonance imaging of dorsolumbar spine showing a central collapse of DV₁₀ and DV₁₁ and anterior wedging of DV₇ and DV₉ causing an indentation upon the thecal sac and compression on the cord.

DISCUSSION

The term “Ankylosing spondylitis” is derived from Greek (“ankylos” meaning “fused” and “spondylos” meaning “vertebra”). It is a chronic inflammatory disease of the axial skeleton, with variable involvement of the peripheral joints and non-articular structures⁽⁵⁾. Overtime the disease process produces extensive remodeling of the spine and makes it more fixed, brittle and osteoporotic⁽⁶⁾. The spine becomes prone to fractures, even after minor trauma⁽⁷⁾. The altered biomechanics as well as a variable degree of peripheral joint arthritis exacerbate gait unsteadiness, increasing susceptibility to falls. Loss of support due to ossification of supportive soft tissues predisposes to displacement of fractured vertebrae, which may result in neurologic deficits^(8,9).

The percentage of patients developing neurological deficits in AS is quite high. A systematic review of the literature, evaluating ninety-three studies revealed that 67.2% of AS patients with vertebral fractures had a neurologic deficit at the time of admission ranging from AIS-A to AIS-D⁽¹⁰⁾. Compared to previously healthy individuals, amongst whom only 0.08% of the patients had a decline in spinal cord function after sustaining traumatic spinal fractures, this percentage was alarmingly high⁽¹¹⁾.

The spinal fractures in AS should preferably be stabilized surgically. If a definite stabilization method is not available for such patients, transfer and manipulation should proceed with maximum caution. Surgical treatment improves neurological status better than conservative treatment but the mortality rate and the clinical outcome are considerably worse as compared to the general trauma population⁽¹⁰⁾. After stabilization of the spine, the subsequent management should be interdisciplinary with spinal surgeon, rheumatologist and physiatrist being the essential components of the team. Comprehensive rehabilitation strategy includes control of pain and stiffness, treating and preventing extra-skeletal manifestations, maintaining function and finally improving the quality of life.

In conclusion, AS is a disease with myriad clinical presentations. It can be asymptomatic in a minority of patients, highlighting the importance of keeping a high index of suspicion, especially in patients presenting with vertebral fractures following relatively minor trauma. The fractures should preferably be stabilized surgically and rehabilitation must follow the surgery to achieve maximum independence in life activities.

REFERENCES

1. Medscape [Internet]. Brent LH, Kalagate R, Patel R. Ankylosing Spondylitis and Undifferentiated Spondyloarthritis. [Cited 2014 Dec 5]. Available from <http://emedicine.medscape.com/article/332945-overview>.
2. Mader R. Atypical clinical presentation of ankylosing spondylitis. *Semin Arthritis Rheum* 1999;29:191-196.
3. Compston A. By Michael O'Brien for the Guarantors of Brain. Saunders Elsevier; 2010. Aids to the investigation of peripheral nerve injuries. Medical Research Council: Nerve Injuries Research Committee. His Majesty's Stationery Office: 1942; pp. 48 (iii) and 74 figures and 7 diagrams; with aids to the examination of the peripheral nervous system. pp. [8] 64 and 94 Figures. *Brain* 2010;133:2838-2844.
4. Ditunno J, Young W, Donovan W, Creasey G. The international standards booklet for neurological and functional classification of spinal cord injury. American Spinal Injury Association. *Paraplegia* 1994;32:70-80.
5. Luo X, Smith HE, Hwang R, Daffner SD. Ankylosing Spondylitis and Diffuse Idiopathic Skeletal Hyperostosis. In: Patel VV, Patel A, Harrop JS, Burger E, editors. *Spine Surgery Basics*. Springer-Verlag Berlin Heidelberg; 2014. P. 475-489.
6. Sambrook PN, Geusens P. The epidemiology of osteoporosis and fractures in ankylosing spondylitis. *Ther Adv Musculoskelet Dis* 2012;4:287-292.
7. Hunter T, Dubo HI. Spinal fractures complicating ankylosing spondylitis. A long-term follow-up study. *Arthritis Rheum* 1983;26:751-759.
8. Lange U, Pape HC, Bastian L, Krettek C. [Operative management of cervical spine injuries in patients with Bechterew's disease]. *Unfallchirurg* 2005;108:63-68.
9. Surin VV. Fractures of the cervical spine in patients with ankylosing spondylitis. *Acta Orthop Scand* 1980; 51:79-84.
10. Westerveld LA, Verlaan JJ, Oner FC. Spinal fractures in patients with ankylosing spinal disorders: a systematic review of the literature on treatment, neurological status and complications. *Eur Spine J* 2009;18:145-156.
11. Verlaan JJ, Diekerhof CH, Buskens E, van der Tweel I, Verbout AJ, Dhert WJ, Oner FC. Surgical treatment of traumatic fractures of the thoracic and lumbar spine: a systematic review of the literature on techniques, complications, and outcome. *Spine (Phila Pa 1976)* 2004;29:803-814.