Local Intra-arterial Thrombolytic Therapy for Patients with Acute Ischemic Stroke

Chun-Chieh Lin, Kwo-Whei Lee[1,3], Chao-Giieh Chang, Che-Hung Yen, Yaw-Don Hsu, Jiann-Chyun Lin, Guann-Juh Chen[2], Shy-Chi Chin[1], Cheng-Yu Chen[1], and Giia-Sheun Peng

Abstract-

Background: Acute thrombolysis for ischemic stroke has been proposed to help some suitable patients. We investigated the application of local intra-arterial thrombolytic therapy to patients with ischemic stroke in different territories of vascular occlusion.

Methods: Ten patients with ischemic stroke, five with middle cerebral artery (MCA) occlusion, three with internal carotid artery (ICA) occlusion, and two with basilar artery (BA) occlusion, were treated by local intra-arterial infusion of urokinase. The end-point was at either reaching the maximal dosage of 1.5 MIU urokinase, early recanalization or suspicion of the occurrence of complications. Stroke scales were used to evaluate their clinical outcomes at the onset, and 7, 30 and 90 days after treatment.

Results: The mean age was 59.4 ±12.2 (range 37 to 73) years; median baseline NIH Stroke Scale was 18.5 ±6.8 (range 8 to 30). Four of five patients with MCA occlusion had good recanalization and one had incomplete recanalization. Two patients with BA occlusion showed good recanalization and improvement of neurological deficits. In contrast, all the patients with ICA occlusion did not show recanalization and the clinical outcomes were poor. Four patients (three with MCA occlusion and one with BA occlusion) had favorable outcomes. Three patients had mild to moderate intracranial hemorrhage. Two patients died of acute myocardial infarction and symptomatic cerebral mass effect with tentorial herniation.

Conclusions: Our results showed that local intra-arterial thrombolysis to treat some acute ischemic stroke due to MCA or BA occlusion might have fewer complications and better outcome than those with ICA occlusion.

Key Words: Stroke, thrombolysis, Urokinase

Acta Neurol Taiwan 2003;12:7-14

INTRODUCTION

In Taiwan, stroke has been the second leading cause of death and a major cause of disability since 1983[(1)]. Several epidemiological studies indicate that cerebral infarction accounts for about 70% of all strokes in Chinese and 90% in Caucasian[(1,2)]. In recent years, more effective and safe treatments have been actively explored for acute ischemic stroke. In the interim, intra-venous and intra-arterial thrombolytic therapy for acute

From the Departments of Neurology, [1]Radiology and [2]Neurosurgery, Tri-Service General Hospital, National Defense Medical Center, Taipei; Department of [3]Radiology, Changhua Christian Hospital.

Received August 7, 2002. Revised September 13, 2002.
Accepted October 30, 2002.

Reprint requests and correspondence to: Giia-Sheun Peng, MD. Department of Neurology, Tri-Service General Hospital, No. 325, Sec. 2, Cheng-Kung Rd., Taipei 114, Taiwan.
E-mail: penggs@seed.net.tw

ischemic stroke has been employed with caution[3,4]. Early recanalization of occluded arteries before the progress of infarction is completed could potentially reduce the degree of injury to the brain. The NINDS study[3] in 1995 indicated that intravenous t-PA treatment was effective in improving clinical outcome in acute ischemic stroke at three months. The treatment for immediate intravenous t-PA depends on the timing, though the heterogenous causes of stroke should be considered as well. There are reports applying intra-arterial infusion of thrombolytic agents to patients with complete carotid territory or vertebrobasilar arterial occlusion[5-11] . These results suggest that direct intra-thrombus delivery of plasminogen activators within six hours after stroke onset can recanalize a greater proportion of major symptomatic occlusion of cerebral arteries[10]. We report ten ischemic stroke patients treated by acute thrombolytic therapy with urokinase through highly selective intra-arterial local administration.

PATIENTS AND METHODS

Subjects

All stroke patients were evaluated in the emergency department by neurologists between October 1998 and September 2000. Ten patients with acute stroke who met the following criteria were recruited to this study.

Protocol of the study

Neurologists at the emergency department took history, performed neurological examinations, and recorded results of four stroke scales[12], including the NIH stroke scale (NIHSS), Barthel index (BI), Glasgow coma scale (GCS), and modified Rankin scale (MRS). The initial evaluations included an electrocardiogram, chest x-ray film, complete blood count, platelet count, prothrombin time, partial thromboplastin time, serum electrolyte determinations, and blood biochemistry analysis. Results of brain computed tomography (CT) were available to the treating physician within 45 minutes of patient's arrival. Cerebral angiography was undergone upon completion of examinations. Follow-up brain CT or magnetic resonance imaging (MRI) scans were performed to rule out hemorrhagic transformation after thrombolytic treatment. All patients were monitored and managed in the intensive care unit for at least 24 hours. The informed consent was obtained from each participant after the possible complications had been explained.

The clinical and neuroradiologic inclusion criteria modified from del Zoppo et al.[11] and Brandt et al.[13] for performing acute thrombolysis included 1) a new acute onset of focal neurological signs in the carotid territory within five hours, and in the vertebrobasilar system which could be delayed according to the clinical condition, 2) a minimal score of > 4 on the NIHSS, 3) age between 21 and 80 years, and 4) normal or minimal early changes of ischemia on brain CT scan. The clinical exclusion criteria included an NIHSS score > 30, coma, minor stroke symptoms, a history of stroke within the previous six weeks, lacunar stroke, seizure at stroke onset, suspected subarachnoid hemorrhage, evidence or history of intracerebral hemorrhage, intracranial neoplasm, uncompensated hypertension (blood pressure > 200/100 mmHg), presumed septic embolus or endocarditis, surgery or trauma (within 30 days), head trauma (within 90 days), active or recent hemorrhage within 14 days, known hereditary or acquired hemorrhagic diathesis, or oral anticoagulation with an international normalized ratio > 1.5. CT scan exclusion criteria were evidence of hemorrhage of any degree, significant mass effect with midline shift, or the presence of an intracranial tumor.

Baseline brain CT scans, with a slice thickness of 4 mm, were unenhanced to assess the presence of intracranial or intracerebral hemorrhage, and major early infarct signs such as diffuse swelling of the affected hemisphere, parenchymal hypodensity or effacement of cerebral sulci. Follow-up brain CT or MRI scans were obtained in all patients to determine the areas of infarction and the presence or absence of hemorrhagic transformation at one to three days after thrombolytic therapy.

The site of occlusion was approached by superselective catheterization, with the use of a 2F microcatheter flushed with a heparinized solution before intra-arterial infusion of urokinase (1 MIU/h in 100 mL NaCl). Infusion was continued either until the vessel was recanalized or until the maximal dose of urokinase (1.5 MIU) was administered. The duration of all treatments

was generally 90 minutes, unless recanalization occurred earlier. Treatment was continued in all patients, not complicated with intracranial hemorrhage, by subcutaneous injection of low molecular weight heparin 1500 IU twice daily for three days.

Clinical outcome was assessed using the four stroke scales specified above at onset, and 7, 30 and 90 days post-thrombolytic therapy[4]. A favorable outcome was defined as an MRS score of 0 or 1 or a BI of 95 to 100, a good outcome as an MRS score of 2 to 3 or a BI of 55 to 90, and a poor outcome as an MRS score of 4 to 5 or a BI of 0 to 50.

Recanalization was assessed by cerebral angiography after treatment and scored as "complete" (Figs. 1A, E), "incomplete" (remaining wall irregularities, filling deficit with remaining thrombus, or occlusion of the branches) or "no".

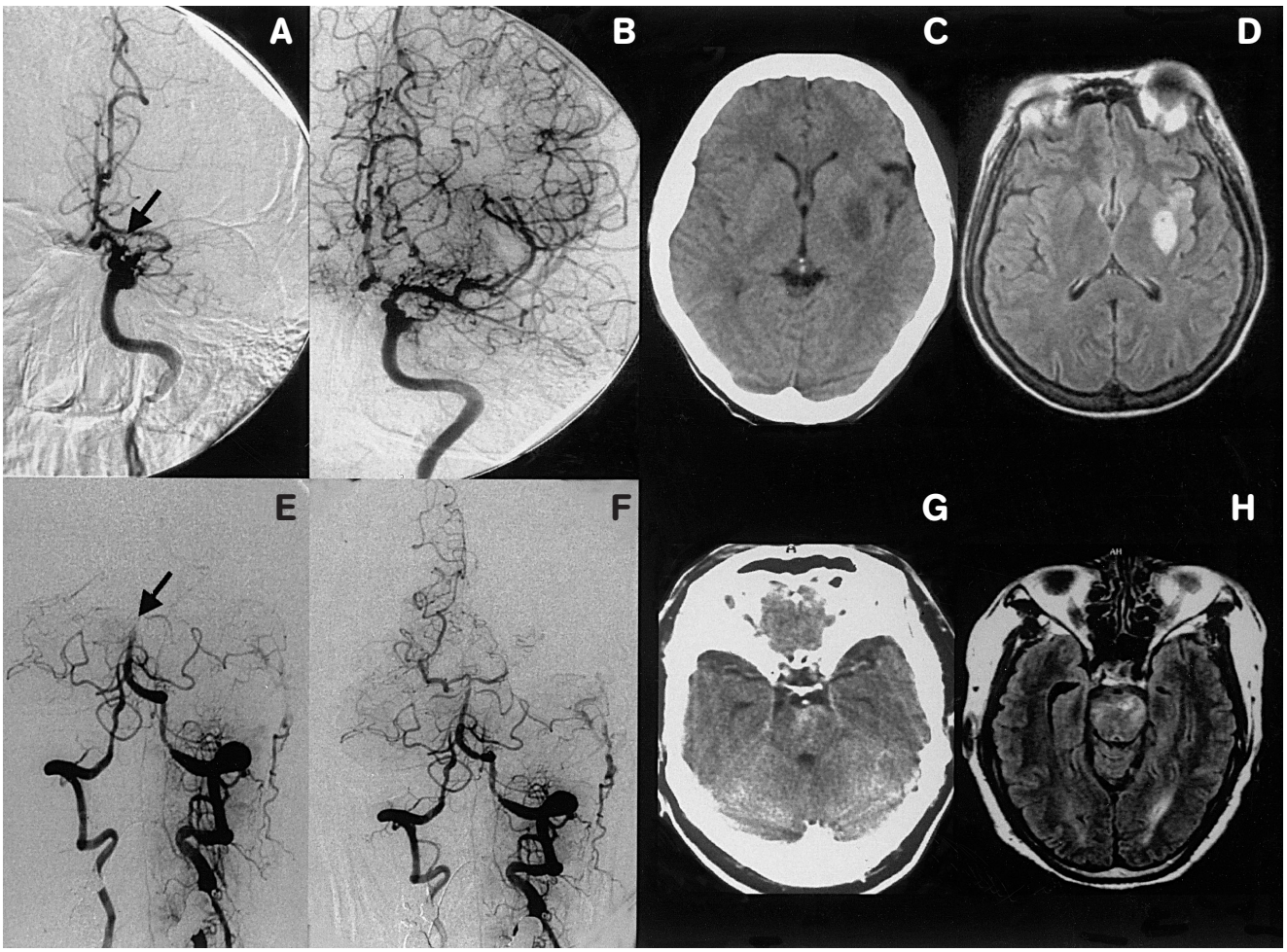

Figure 1. Complete recanalization after thrombolytic treatment.
Patient 2: The ipisilateral left internal carotid artery angiographic studies demonstrate total occlusion of the proximal M1 segment of the middle cerebral artery (arrow) and the excellent filling of the anterior cerebral artery before thrombolytic treatment (1A), and show dissolution of emboli and recanalization of the left middle cerebral artery after infusion of 600,000 U of urokinase (1B). The cerebral infarction in the left basal ganglion is detected by the brain computed tomography (CT) (1C) and magnetic resonance imaging (MRI) scans (1D) after thromholytic therapy 1 and 24 hours, respectively. Patient 9: The vertebral angiogram shows total occlusion at the middle segment of the basilar artery (arrow) (1E) and recanalization of the basilar artery and its branches after infusion of 480,000 U of urokinase (1F). Brain CT scans disclose a low-density lesion with enhancementin the left pons 1 hour after thnombolytic therapy (1G). A lesion of high signal intensity is located at the pons on brain MRI scans (1H) two weeks after thrombolytic therapy.

Table 1. *Clinical characteristics: demographic data, risk factors, and outcome*

Pt. No	Age/sex	SBP/DBP	Risk factor	Occlusion site	Time (hr)	UK (MU)	Rec	Complications	Others
1	57/F	145/74	MVD	M1	4.0	0.30	C	-	-
2	37/F	154/84	MVD	M1	2.5	0.60	C	-	-
3	46/M	150/80	Hyp/CAD/Alc	M1	4.7	0.72	C	-	-
4	55/M	120/80	Hyp	M1	3.0	0.72	IC	Craniotomy/SAH	-
5	69/F	150/90	Hyp/MVD	M2	2.5	0.12	C	-	Expired, MI
6	71/F	173/103	Hyp	ICA	3.5	1.50	N	-	Expired,
7	64/M	140/80	Hyp/AF	ICA	3.5	1.08	N	Craniotomy/PHE	-
8	71/M	145/88	Hyp/Sm	ICA	4.0	1.08	N	Craniotomy	-
9	51/M	146/88	Hyp/Sm/AF	BA	19.0	0.48	C	-	-
10	73/M	144/70	Hyp	BA	17.5	0.78	C	IVH	-

AF: atrial fibrillation; BA: basilar artery occlusion; C: complete; CAD: coronary artery disease; DBP: diastolic blood pressure; Hyp: hypertension; IC: incomplete; ICA: internal carotid artery occlusion; ICH: intracranial hemorrhage; IVH: intraventricular hemorrhage; MCA: middle cerebral artery; M1 or M2: M1 or M2 segment of MCA; MU: MegaUnits; MVD: mitral valve disease; N: no; P: partial; PHE: parenchymal hematoma; Pt.: patient; Rec: recanalization; SAH: subarachnoid hemorrhage; SBP: systolic blood pressure; Sm: smoking; T: total; Time: interval between stroke onset and treatment; UK: urokinase.

RESULTS

Patient Characteristics (Table 1)

Ten patients, six male and four female, aged 37 to 73 years, with acute ischemic stroke were studied. Ancillary conditions included hypertension (n = 8), heart disease (n = 6), smoking (n = 2), and alcoholism (n = 1). The arterial occlusions identified angiographically included an isolated M1 (n = 4) or M2 (n = 1) segment of the middle cerebral artery (MCA), in the proximal part or the siphon of internal carotid artery (ICA) (n = 3), in middle of the basilar artery (n = 1) and at the top of the basilar artery (BA) (n = 1). Six patients presumably had embolic events because of clinical features and risk sources of cardiac embolism (three with mitral valve disease, two with atrial fibrillation and one with old myocardial infarction).

Interval between symptom onset and treatment

Eight patients with carotid territory occlusion received urokinase (0.3 to 1.5 MIU) within 3.5 hours after the onset of apparent symptoms. Other patients with basilar occlusion received thrombolytic treatment (0.48 to 0.78 MIU) at about 18.3 hours after the onset of symptoms.

Clinical outcomes (Table 2)

Evaluation of the recanalization efficacy was made on the basis of cerebral angiography. Among these patients, arterial recanalization was complete in six patients (four in MCA occlusion and two in BA occlusion) (Figs. 1A-H), incomplete in one patient with MCA occlusion and no recanalization in three patients with ICA occlusion. Clinically, three patients with acute MCA stroke demonstrated favorable outcomes at the first week and three months post-treatment. One patient with acute BA occlusion also showed favorable outcome at three months post-treatment. Two patients died after treatments. One patient (Figs. 2A-B) with acute MCA occlusion showed improvement in neurological deficits but died due to acute myocardial infarction on the first day post-therapy. Another patient with ICA occlusion (Figs. 2C-E) died of massive cerebral edema with transtentorial herniation. Three patients had craniotomy due to acute neurological deterioration caused by brain edema. They all survived with moderate to severe neurological deficits at three months post-treatment.

Intracranial hemorrhage

Hemorrhagic transformation within 24 hours of treatment occurred in three patients. One patient received only conservative treatment for mild neurological deterioration, and two patients underwent craniotomy to reduce intracranial pressure caused by cerebral edema, not by hematoma, resulting in mass effect and midline shift.

Complications of angiography

No patients in this study deteriorated during angiography, before or after the infusion.

Table 2. *Clinical outcome before treatment and during the follow-up period*

Pt. No.	NIHSS				GCS				BI				MRS			
	Pre	Post			Pre	Post			Pre	Post			Pre	Post		
		1w	1m	3m		1w	1m	3m		1w	1m	3m		1w	1m	3m
1	8	0	0	0	15	15	15	15	45	100	100	100	4	0	0	0
2	19	0	0	0	11	15	15	15	10	100	100	100	4	0	0	0
3	16	4	4	3	13	15	15	15	20	95	100	100	4	1	1	1
4	19	18	18	10	9	12	15	15	0	20	40	90	5	5	4	2
5	15	42	E		11	3	E		20	0	E		4	6	E	
6	24	E			8	E			10	E			5	E		
7	18	24	24	9	12	8	15	15	0	0	20	20	5	5	4	4
8	26	29	29	29	10	6	10	10	0	0	0	0	5	5	5	5
9	30	18	18	18	6	10	10	10	0	5	5	5	5	5	5	4
10	10	26	26	6	13	14	15	15	20	20	95	95	4	3	1	1

BI: Barthel Index; E: expired; GCS: Glasgow coma scale; MRS: Modified Rankin Scale; NIHSS: National Institutes of Health Stroke Scale; Pre: pre-thrombolytic treatment; Post: post-thrombolytic treatment; Pt: patient; w: week; m: month.

DISCUSSION

With advances in clinical and radiologic assessment, and better understanding of the pathophysiology of brain ischemia, thrombolytic therapy has emerged to be a feasible intervention in acute stroke. Previous studies indicated that an ischemic penumbra exists and some clinical deficits are potentially reversible[14]. In experimental animals, acute restoration of blood flow may salvage the ischemic but viable tissue[15]. Limited clinical experiences suggest that compared with intravenous delivery, direct intra-thrombus delivery of plasminogen activators within six hours of stroke onset can recanalize a greater proportion of major symptomatic cerebral arterial occlusions[5-11]. The local delivery of thrombolytic agents, at or within the occluding thrombus, has the advantage of providing a higher concentration of the particular thrombolytic agent where it is needed while minimizing the concentration systemically. Hence, local intra-arterial thrombolysis has the potential for greater efficacy in arterial recanalization, and greater safety in reducing the risk of hemorrhage[16].

In our study, four of five patients with MCA occlusion had good recanalization and better outcomes. The four measures of outcomes at 7 to 90 days demonstrated a 60% rate of favorable outcome. Intraparenchymal cerebral hemorrhage was shown in one patient with only mild handicap at three months post treatment. One patient with MCA occlusion had a quick recovery from neurological deficits, but died of myocardial infarction afterward (Figs. 2A-B). Although the time interval between stroke and treatment was 18.3 hours, good recanalization and recovery in BA occlusion could be achieved. Three patients with internal carotid occlusion showed no recanalization even after higher dosage of urokinase (1.1 to 1.5 MIU) was administered. One died of massive cerebral edema with transtentorial herniation (Figs. 2C-E). The others received craniotomy to reduce the intracranial pressure within one day. Their clinical outcomes were poor.

Treatment of ischemic stroke is contemplated because of the poor prognosis associated with the natural history of disease. In patients with non-treated MCA occlusion, the probability of returning to a favorable lifestyle is fairly low (20%), although the acute mortality is also low (12% to 28%)[17-19]. Left untreated, BA thrombosis also has a high mortality, so the risks of conservative therapy are substantial. Hacke et al. reported that given conventional treatment, only 3 of 22 (13.6%) survived vertebrobasilar occlusion. For such ischemic strokes, early recanalization may be fundamental to clinical improvement[6,17-20]. Anecdotal evidence and case series have shown better efficacy in recanalization with intra-arterial thrombolysis (44% - 87%) than with intravenous thrombolysis (21% - 43%). Two randomized control studies of intra-arterial thrombolysis using prourokinase demonstrated a relatively high recanalization rate (58% and 67% versus 14% and 17% for placebo) in acute MCA occlusion[11,18]. Moreover, in the studies of Hacke et al.[7] and Wijdicks et al.[21], vertebrobasilar strokes post-

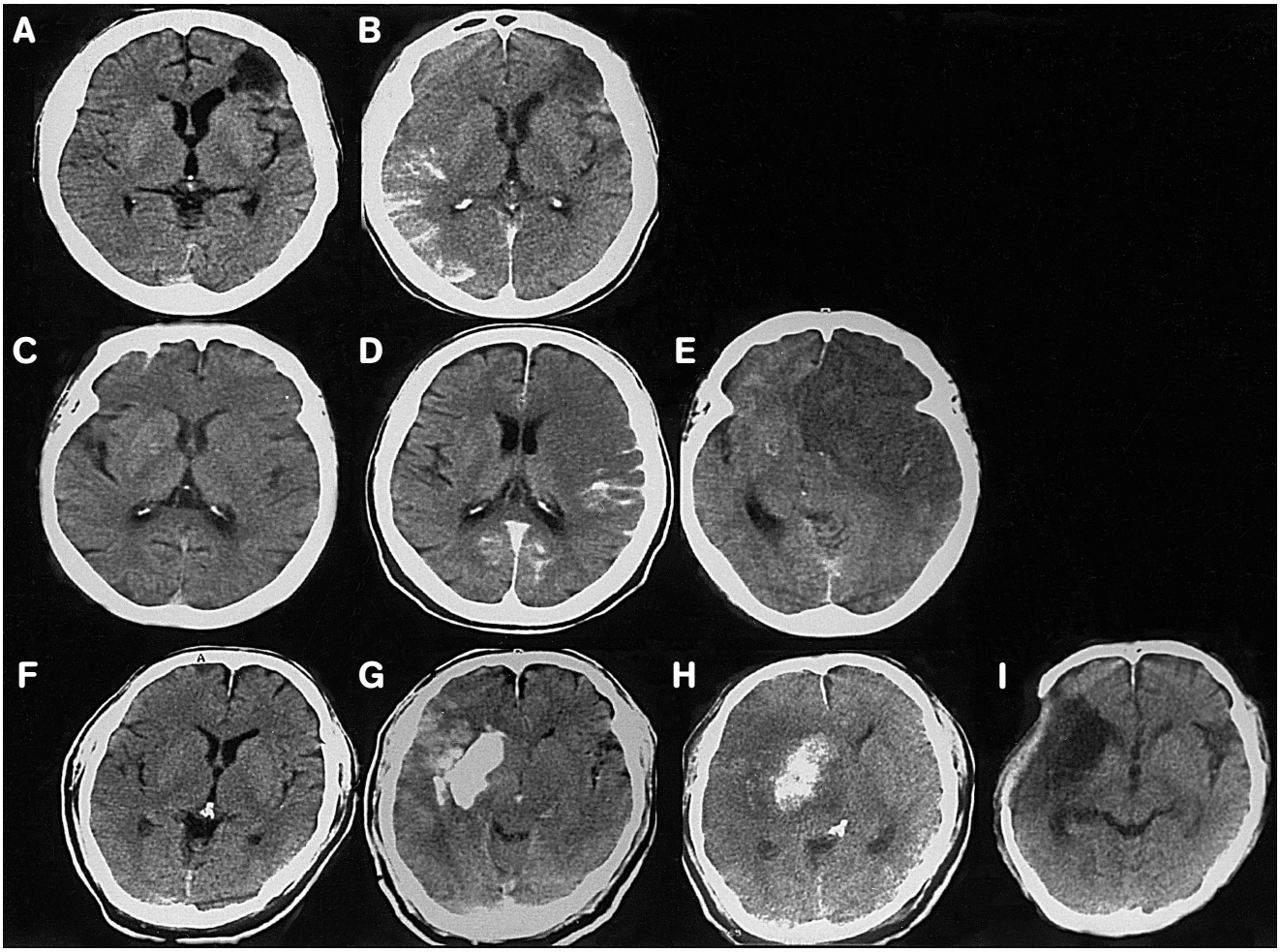

Figure 2. Brain computed tomography (CT) scans in three patients treated with urokinase for acute infarction. Brain CT scans of the patient 5 with acute right middle cerebral artery (MCA) occlusion and an old infarct in the left frontal area show garlandlike enhancement without hemorrhagic transformation in the cerebral cortex on the acute post-thrombolytic scan (B) compared with the pre-thrombolytic scan (A). Neuroimaging studies of the patient 6 with acute left internal carotid artery (ICA) occlusion reveal normal structures on the acute brain CT scan (C) and lesions with garlandlike enhancement with minimally decreased densities in the left MCA and anterior cerebral artery (ACA) territories on the acute post-thrombolytic scan (D). There is significant mass effect with compression of the ventricular system on the left side resulting in marked displacement of midline structures on post-thrombolytic 24 hours scans (E). Brain CT scans of the patient 7 with acute right ICA occlusion show normal structures (F). On acute post-thrombolytic scans, there is an isodense hematoma in the right basal ganglia with enhancement of the cerebral cortex and mild hypodense areas in the territories of the right ACA and MCA (G). On scans obtained 24 hours post-thrombolytic therapy, there are hematoma of the same size and conspicuous brain edema with compression of the ventricular system on the right side resulting in marked displacement of midline structures (H). There is a hypodense lesion in the right MCA territory with bony defect on scans performed 2 months after thrombolytic therapy and craniotomey (I).

thrombolysis with 44% and 78% recanalization rate were associated with 53% and 55% favorable outcome, respectively.

Detailed information on recanalization rate, safety, and clinical benefit of thrombolytic therapy in patients with ICA occlusion is lacking. A few studies[22,23] showed that a higher mortality rate in patients with complete ICA occlusion, particularly if the MCA trunk was occluded, which resulted in more severe and more extensive ischemic edema. Janse et al.[22,23] reported that intravenous or intra-arterial treatment with thrombolytic drugs failed to recanalize the vascular obstruction, it did

not improve the prognosis of ICA occlusion over that of the natural course. In the current series, three patients had long segment occlusion of ICA concomitant with MCA occlusion, and lacked sufficient collaterals. Absence of recanalization and poor clinical outcomes were noted in these patients.

The risk of symptomatic ICH significantly increases with intra-venous or intra-arterial thrombolytic therapy. In the studies of NINDS[3] and ATLANTIS[24] showed that the overall rates of symptomatic ICH were 6.4% and 7.0% for the rt-PA-treated patients compared with 0.6% and 1.1% for the placebo-treated patients, respectively. The PROACT II study[11] indicated that the prourokinase group had a significant higher rate of ICH than the heparin group (35% vs 13%). In this study, there were six patients with adverse events, but only three of them suffered from intracranial hemorrhage. One was with minimal intraventricular hemorrhage and the others were with moderate parenchymatous hematoma. However, their outcomes were not related to the size of intracranial hemorrhage but to the natural course of underlying disease.

In conclusion, the present study demonstrated that local intra-arterial thrombolytic therapy might be implemented for a minority of patients with acute occlusion in the MCA and BA, but not adequate in those with ICA occlusion.

ACKNOWLEDGMENT

This work was supported by grants from the Tri-Service General Hospital (TSGH-C-89-64; TSGH-C-90-50)

REFERENCES

1. Hung TP. Cerebrovascular disease in the Taiwan area: past, present and future. J Formos Med Assoc 1993;92:S103-111.
2. Hu HH, Tzeng SS. Ischemic stroke in Taiwan. J Formos Med Assoc 1994;93:S6-12.
3. The National Institute of Neurological Disorder and Stroke rt-PA Stroke Study Group. Tissue plasminogen activator for acute ischemic stroke. N Engl J Med 1995;333:1581-7.
4. Burnette WC, Nesbit GM, Barnwell SL. Intra-arterial thrombolysis for acute stroke. In: Nesbit GM, Neuroimaging Clinics of North America, Vol 9. “Acute Ischemic Stroke”, W.B. Saunders, 1999:491-508.
5. Mori E, Yoneda Y, Tabuchi M, et al. Intravenous recombinant tissue plasminogen activator in acute carotid artery territory stroke. Neurology 1992;42:976-82.
6. Mori E, Tabuchi M, Yoshida T, et al. Intracarotid urokinase with thromboembolic occlusion of the middle cerebral artery. Stroke 1988;19:802-12.
7. Hacke W, Zeumer H, Ferbert A, et al. Intra-arterial thrombolytic therapy improves outcome in patients with acute vertebrobasilar occlusive disease. Stroke 1988;19:1216-22.
8. Zeumer H, Freitag HJ, Zanella F, et al. Local intra-arterial fibrinolytic therapy in patients with stroke: urokinase versus recombinant tissue plasminogen activator (r-TPA). Neuroradiology 1993;35:159-62.
9. del Zoppo GJ, Poeck K, Pessin MS, et al. Recombinant tissue plasminogen activator in acute thrombotic and embolic stroke. Ann Neurol 1992;32:78-86.
10. Sasaki O, Takeuchi S, Koike T, et al. Fibrinolytic therapy for acute embolic stroke: intravenous, intracarotid, and intra-arterial local approaches. Neurosurgery 1995;36:246-53.
11. del Zoppo GJ, Higashida RT, Furlan AJ, et al. PROACT: a phase II randomized trial of recombinant pro-urokinase by direct arterial delivery in acute middle cerebral artery stroke. PROACT Investigators. Prolyse in Acute Cerebral Thromboembolism. Stroke 1998;29:4-11.
12. Yen CH, Lin CC, Chang CG, et al. Reliability of stroke scales in Chinese version for acute ischemic stroke patients. J Med Sci 2000;20:225-36.
13. Brandt T, von Kummer R, Müller-Küppers M, et al. Thrombolytic therapy of acute basilar artery occlusion: variables affecting recanalization and outcome. Stroke 1996;27:875-81.
14. Albers GW. Expanding the window for thrombolytic therapy in acute stroke. Stroke 1999;30:2230-7.
15. Zivin JA, Fisher M, De Girolami U, et al. Tissue plasminogen activator reduces neurological damage after cerebral embolism. Science 1985;230:1289-92.
16. Brott T. Reopening occluded cerebral arteries. In: Bogousslavsky J, ed. Acute Stroke Treatment. 1st ed. London: Martin Dunitz, 1997:109-48.

17. Chambers BR, Norris JW, Shurvell BL, et al. Prognosis of acute stroke. Neurology 1987;37:221-5.
18. Furlan A, Higashida R, Wechsler L, et al. Intra-arterial prourokinase for acute ischemic stroke. The PROACT II study: a randomized controlled trial. Prolyse in Acute Cerebral Thromboembolism. JAMA 1999;282:2003-11.
19. Yoshimoto T, Ogawa A, Seki H, et al. Clinical course of acute middle cerebral artery occlusion. J Neurosurg 1986; 65:326-30.
20. Brott TG, Haley EC, Levy DE, et al. Urgent therapy for stroke: Part I. Pilot study of tissue plasminogen activator administered within 90 minutes. Stroke 1992;23:632-40.
21. Wijdicks EF, Nichols DA, Thielen KR, et al. Intra-arterial thrombolysis in acute BA thromboembolism: the initial Mayo Clinic experience. Mayo Clin Proc 1997;72:1005-13.
22. Marzewski DJ, Furlan AJ, St Louis P, et al. Intracranial internal carotid artery stenosis: longterm prognosis. Stroke 1982;13:821-4.
23. Bogousslavsky J, Regli F. Prognosis of symptomatic intracranial obstruction of internal carotid artery. Eur Neurol 1983;22:351-8.
24. Clark WM, Wissman S, Albers GW, et al. Recombinant tissue-type plasminogen activator (Alteplase) for ischemic stroke 3 to 5 hours after symptom onset: the ATLANTIS Study: a randomized controlled trial. JAMA 1999;282: 2019-26.